

Chondromyxoid Fibroma of the Maxilla: A Rare Presentation

Manasa Ravath*, Noopur Kulkarni**, Nilesh Birajdar***

*Reader ***Senior Lecturer, Dept. of Oral Pathology and Microbiology, Pandit Deendayal Upadhyay Dental College, Solapur, Maharashtra 413255, India. **OMFS, Dental Faculty, Birajdar Hospital, Solapur, Maharashtra 413001, India.

Abstract

CMF is said to be the most uncommon benign tumors in the oral cavity. Very few cases in the oral cavity have been reported so far. Its uniqueness & rare occurrence in the Head & Neck area has made us report the dental image of the same.

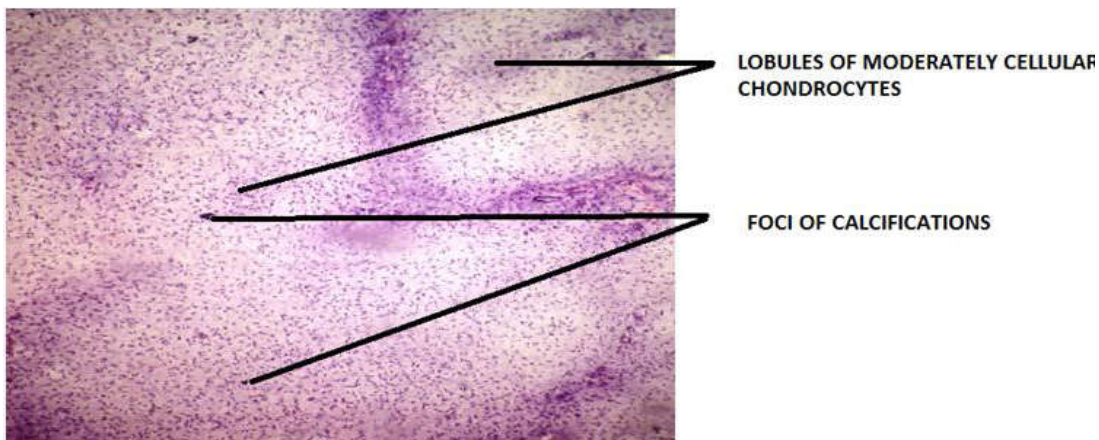
Keywords: Chondromyxoid Fibroma; Benign Tumor; Giant Cell Tumor.

Chondromyxoid Fibroma is documented to be the rarest benign tumors of cartilaginous origin, accounting for less than 0.5% of bone tumors [1]. Chondromyxoid Fibroma is seen growing outside the cartilage, characteristically in the flared end of a long bone like shin bone / thigh bone. Other locations could be femur near the knee, hip, foot bones & so on [2].

An association of CMF with certain chromosomal translocations was noted. Oncogenic activation, over expression of Glutamate receptor gene (GRM), recombining with other partner genes are some known causes [3]. Rate of malignancy transformation is very rare & this lesion can be misdiagnosed as a de novo Chondrosarcoma or Myxosarcoma [3].

The incidence rate of CMF is exceedingly rare in the Head & Neck region. It is more commonly seen in the maxilla, sphenoid & ethmoid sinuses. Formerly it was classified as a Myxoma or a myxomatous variant of Giant cell tumor [4].

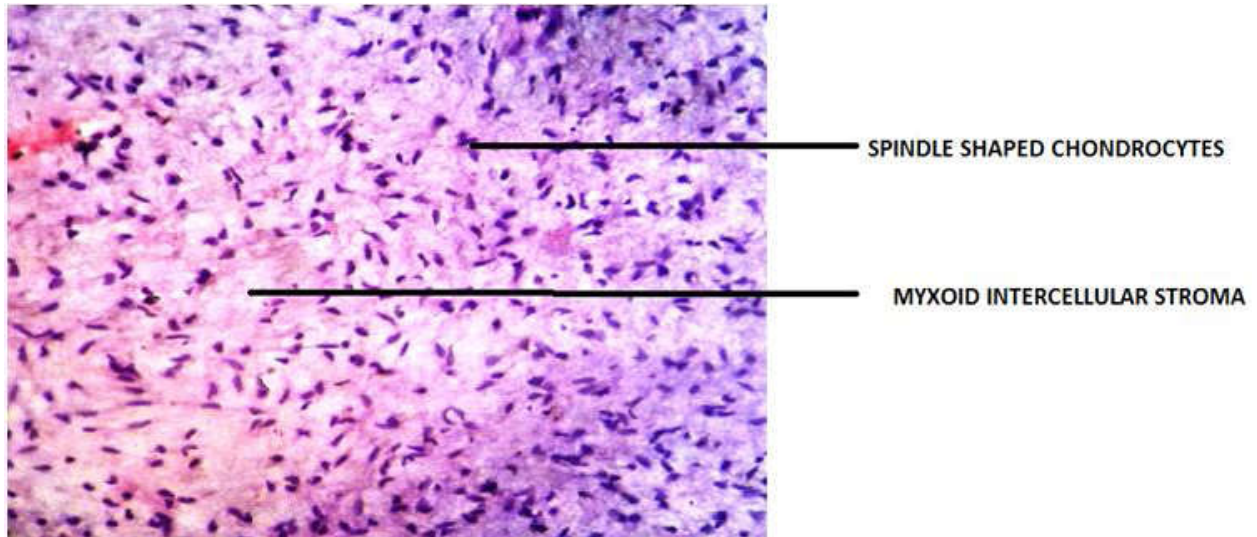
The given image is a 40X view of a section of a CMF of the maxillary region. The chondrocytes are spindle shaped, distributed in sparsely cellular lobules of myxoid or chondroid matrix as an intercellular substance. Few pleomorphic cells are also evident. Focal areas of calcification are evident along with some giant cells scattered in the myxoid tissue.



Images 1 & 2 are lower magnification & higher magnification views of CMF respectively

Corresponding Author: Noopur Kulkarni, Senior Lecturer, Dept. of Oral Pathology & Microbiology, Pandit Deendayal Upadhyay Dental College, Solapur, Maharashtra 413255, India.
E-mail: drnoopurmanagoli@gmail.com

(Received on 07.11.2017, Accepted on 25.11.2017)



Images 1 & 2 are lower magnification & higher magnification views of CMF respectively

Conclusion

We are presenting this Histopathology image because of the rare incidence of Chondromyxoid Fibroma in the Head & Neck region, this lesion being most prevalent in the upper & lower limb area.

2. Ortho Info AAOS (American Academy Of Orthopaedic Surgeons).
3. Chondromyxoid Fibroma. Medscape updated Sep 13 , 2016 Michael S Clarke, MD.
4. Annals of Maxillofacial Surgery .CMF of the mandible. Case report & ROL. Benjamin Fomete , O.O, Adeson , L Olayemi 2014.

References

1. Cureus. Chondromyxoid Fibroma : A rare case report & review of literature. Rishit Soni, Chirag Kapoor.
-